

## TUBERCULOUS VASCULITIS - A RARE CASE PRESENTATION

Nivetha Raghupathy<sup>1</sup>, Nandeibam Belinda<sup>1</sup>, Jayakumar K T<sup>3</sup>

<sup>1</sup>Junior Resident, Department of General Medicine, SRM Medical college Hospital and Research Centre, Kattankulathur, Tamil Nadu, India

<sup>2</sup>Professor, Department of General Medicine, SRM Medical college Hospital and Research Centre, Kattankulathur, Tamil Nadu, India

Received : 30/05/2023  
Received in revised form : 01/07/2023  
Accepted : 15/07/2023

**Keywords:**

Tuberculoma, Tuberculous meningitis, Antituberculous drugs, Hydrocephalus, Tuberculous vasculitis

Corresponding Author:

**Dr. Nivetha Raghupathy,**  
Email: nivethamdr@gmail.com

DOI: 10.47009/jamp.2023.5.4.290

Source of Support: Nil,  
Conflict of Interest: None declared

*Int J Acad Med Pharm*  
2023; 5 (4); 1456-1458



### Abstract

**Background:** Tuberculous vasculitis, a dreadful complication of neurological tuberculosis is rarely seen in the absence of disseminated tuberculosis or immunocompromised state. This case of tuberculous cerebral vasculitis is being reported to highlight that this complication should always be expected in a patient with neurological tuberculosis with or without treatment. Thereby, can save many young adults who lose their lives to neurological tuberculosis. **Case Presentation:** Here, we present a 23-year-old male, with no known comorbidities and no significant addictions, who presented with complaints of fever, headache, neck pain and vomiting. After evaluation, patient was diagnosed with multiple tuberculoma of brain and tuberculous meningitis. Patient was treated accordingly with Antituberculous drugs, corticosteroids and other supportive medications. Patient was discharged since his general condition improved. Patient was brought to casualty 1 month after discharge with complaints of inability to move right upper and lower limbs, inability to talk, reduced responsiveness. Patient was not compliant with antituberculous drugs and corticosteroids. This time, patient was diagnosed with communicating hydrocephalus and acute infarct in left midbrain and thalamus. Patient was admitted under intensive care unit and continued treatment. Patient condition worsened and repeat imaging showed multiple infarcts involving all the arterial territories (Bilateral anterior, middle and posterior brain circulation). Despite all effective resuscitative measures, this patient had poor prognosis. **Conclusion:** This case report highlights that isolated neurological tuberculosis can occur even in a young immunocompetent male with progression to rare complication of vasculitis involving bilateral anterior, middle and posterior circulation of the brain. This arterial distribution of tuberculous vasculitis to the best of our knowledge is being described in the literature for the first time.

## INTRODUCTION

Isolated Neurological tuberculosis is a rare disease, especially in an immunocompetent young adult. Tuberculous meningitis, being the most common manifestation of neurological tuberculosis has 100% mortality in untreated cases. Literature has cited vascular involvement in tuberculous meningitis is frequently under reported.<sup>[1]</sup> Stroke in tuberculous meningitis occurs in 15-57% of patients with advance and severe disease.<sup>[2]</sup>

The spectrum of vascular pathology in tuberculous meningitis includes arteritis, spasm of arteries, arterial thrombosis, and compression of larger arteries by a thick exudate. These changes reduce cerebral perfusion resulting in various stroke syndromes. It has generally been reported that arteritis mainly affects perforating branches of major arteries at the base of the brain resulting in basal

ganglia infarction that is commonly seen in Tuberculous meningitis.<sup>[3-5]</sup>

In our case report, we present a young male, who developed tuberculous vasculitis in all the arterial territories of the brain which is a rare presentation of tuberculous vasculitis.

## CASE REPORT

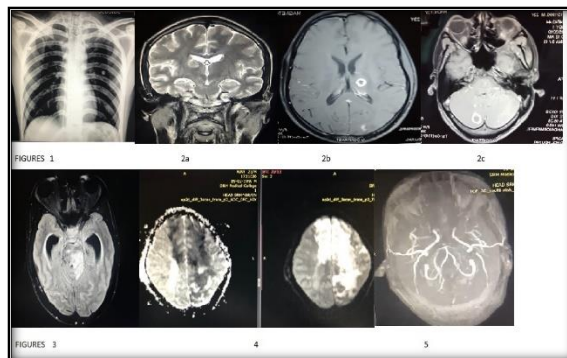
Here, we present a case, a 23-year-old male, web designer by occupation, with no known comorbidities and no significant addictions, presented with primary complaints of fever, headache, neck pain for 1-month duration and vomiting for 3 days duration. Upon physical examination, patient had neck stiffness, Kernig's and Brudzinski's sign was positive. Rest of the neurological examination and his auscultatory findings were clinically normal. Provisional

diagnosis of fever under evaluation and to rule out meningitis was made.

Routine blood investigations done which included complete blood count, electrolytes, renal and liver function tests, urine analysis were within normal limits. ESR was 53mm/hr. Fever profile (Dengue NS1, leptospirosis serology, Malarial Parasite, Microfilaria) and HIV, Hepatitis B, VDRL were negative. Chest x ray [Figure 1], USG Abdomen, ECG were normal. Sputum gram stain, culture and Acid-fast bacilli was negative. Brain imaging revealed multiple hypointense lesions with complete ring enhancement – granulomatous inflammatory lesions, likely tuberculoma [Figure 2a, 2b, 2c]. CSF analysis was done which revealed mycobacterium tuberculosis ( $2.4 \times 10^3$ ), positive ADA, protein – 75mg/dl, glucose – 55mg/dl, 18 cells/mm<sup>3</sup> (lymphocyte predominant). Ophthalmic examination revealed no papilledema or choroidal tubercles. Patient was initiated on Antitubercular drugs (4 tablets of 4 FDC/day), continued treatment with dexamethasone, mannitol, levetiracetam. Patient general condition improved within 3 weeks duration and he was discharged and advised to continue ATT and corticosteroids and regular follow up. Liver function tests at the time of discharge were within normal limits.

Patient was brought to casualty after 1 month with complaints of inability to use right upper and lower limbs, inability to talk, reduced responsiveness and vomiting for 2 days duration. History revealed that the patient was not compliant with ATT and steroids. On physical examination, patient was drowsy, not oriented to time, place, person, obeying simple commands occasionally by nodding head. His pulse rate was 60/min, temperature of 99.2-degree fahrenheit, blood pressure, respiratory rate and saturation under room air was normal. His neurological examination revealed GCS of 11/15, bilateral pupils 3mm and sluggishly reacting to light, motor aphasia was present, no cranial nerve involvement, power in the right upper and lower limbs were 1/5 with normal tone and extensor plantar response on the right side. Blood investigations revealed ESR of 92mm/hr, CRP of 6 mg/dl (positive) and other tests were within normal limits. Chest x ray during second admission was also within normal limits. MRI Brain was done which revealed communicating hydrocephalus and left thalamus and midbrain acute infarcts [Figure 3]. Ophthalmologist opinion obtained and there was no evidence of papilledema or choroid tubercles. Patient was restarted on ATT and corticosteroids with other supportive medications. Right sided ventriculoperitoneal shunting was done by Neurosurgeon team. Despite continuous ICU care, patient developed GTCS with respiratory distress. Repeat brain imaging showed multiple cerebral infarcts involving bilateral anterior, middle and posterior brain circulation [Figure 4]. Cerebral angiography was done which showed thinning of arteries with beaded appearance and loss of flow void

in bilateral anterior cerebral, middle cerebral and posterior cerebral arteries [Figure 5]. Anti-nuclear antibody (ANA), Anti phospholipid antibodies (APLA) tests were done in view of vasculitis and found to be negative. Despite continuous intensive care, patient condition deteriorated further and developed hypotension and was put on inotropes with no spontaneous respiratory attempts. Brainstem reflexes were absent. Unfortunately patient could not be saved.



## DISCUSSION

- Neurological tuberculosis accounts for 5 to 10% of the cases of extrapulmonary tuberculosis.<sup>[6]</sup>
- More common in children.
- High morbidity and mortality even with modern day antitubercular treatment.

### Pathogenesis of Neurological tuberculosis

Following Primary infection or late reactivation of TB, Bacillemia occurs, which results in Scattered tuberculous foci with tubercles in brain, meninges or adjacent bone.<sup>[7]</sup>

when a sub-ependymally located tubercle ruptures, the infectious material will get delivered into the subarachnoid space, producing Intense hypersensitivity reaction and Inflammatory response.<sup>[8]</sup>

Inflammatory changes are most marked at the base of brain

1. Proliferative arachnoiditis
2. Vasculitis with resultant aneurysm, thrombosis and infarction
3. Communicating hydrocephalus

### Tuberculous Vasculitis

Tuberculous vasculitis commonly affect vessels that traverse basilar or spinal exudate or located within the brain itself and the frequently involved vessels are Terminal portion of internal carotid artery and Proximal middle cerebral artery in the sylvian fissure. Meningeal veins can get involved resulting in phlebitis and thrombosis. Multiple lesions are common with variety of stroke syndromes involving basal ganglia, cerebral cortex, pons, cerebellum.

The common risk factors for the development of tuberculous vasculitis are female gender, Coexisting HIV infection, Prolonged pre-existing symptoms, High cerebrospinal fluid neutrophil count, Meningeal enhancement on initial brain imaging, stage II or III

of meningitis, Tuberculomas, Presence of hydrocephalus

The pathogenesis of tuberculous vasculitis is Panarteritis of the basal arteries of circle of Willis and also of the lenticulostriate arteries which occurs due to an inflammatory reaction within the subarachnoid spaces and basal cisterns producing vasculopathy and steno-occlusive changes and ultimate precipitation of ischemic events. The Other mechanisms are vessel infringement by the inflammatory exudate – Vascular narrowing, vasospasm mediated by the vasoconstrictive substances or a immune mediated response.

According to an autopsy study by Chatterjee et al, the most common arterial territory involved in tuberculous vasculitis is Middle cerebral artery territory followed by basilar artery, then posterior cerebral artery, MCA + BA in 1% and MCA + BA + PCA in < 1% of the affected individuals.<sup>[1]</sup> Our case report involving all the arterial territories is very rare presentation involving Bilateral ACA + MCA + PCA + BA which is first ever reported in the literature.

## CONCLUSION

- Vascular complications of TB are life threatening.
- Despite development of recent advances in the understanding of pathology, pathogenesis and also treatment with modern day ATT, only limited data is available on the TB vasculitis.
- TCV can develop in patients even on treatment with antituberculous drugs, corticosteroids, and aspirin
- Role of cerebral blood flow augmentation procedures in improving the quality of life in these individuals has not been widely studied still.

- Finally, the delayed clinical response in TBM patients with hydrocephalus and CNS vasculitis can have two different reasons. Firstly, it may suggest the delayed initiation of anti-tuberculous treatment so the complications had already been set in and secondly, decreased availability of anti-tuberculous drugs at the target area from beginning due to decreased perfusion pressure (decreased intra-luminal flow and pressure in vasculitis and increased extra-vascular pressure in hydrocephalus).

## REFERENCES

1. Chatterjee D, Radotra B D, Vasishta R K, Sharma K. Vascular complications of tuberculous meningitis: An autopsy study. *Neurol India* 2015;63(6):926-32.
2. Misra J K, Kalita J, Maurya P K. Stroke in tuberculous meningitis. *J Neurol Sci* 2011;303(1-2):22-30.
3. Murthy JM. Tuberculous meningitis: The challenges. *Neurol India* 2010;58:716-22.
4. Shankar SK, Santosh V, Mahadevan A, Yasha TC, Satishchandra P. Pathology of cerebral vasculature in neurotuberculosis-some observations. In: Mehta VS, Misra UK, editors. *Progress in Neurosciences*. New Delhi: Neurological Society of India; 2001. p. 134-41.
5. Dastur DK, Lalitha VS, Udani PM, Parekh U. The brain and meninges in tuberculous meningitis-gross pathology in 100 cases and pathogenesis. *Neurol India* 1970;18:86-100.
6. Longo DL, Fauci AS, Kasper DL, Hauser SL, Jameson JL, Loscalzo J, EDS. *Harrison's Principles of Internal Medicine*, 20th edition. New York: McGraw-Hill; 2018. P. 1244-45.
7. WHO Global Tuberculosis Report 2020: Global Tuberculosis Programme-TB reports. Vol. 2020. World Health Organisation; 2020. P. 23-70.
8. Nicholas A, Kim K S, Bishai W R, Jain S K. Pathogenesis of Central Nervous System Tuberculosis. *Curr Mol Med*. 2009 Mar; 9(2): 94–99.